

IN THE CORONERS COURT
OF VICTORIA
AT MELBOURNE

Court Reference: COR 2011 / 1267

FINDING INTO DEATH WITH INQUEST

Form 37 Rule 60(1)

Section 67 of the Coroners Act 2008

Inquest into the Death of: ZORAN GEORGIEVSKI

Delivered On: 10 April 2015

Delivered At: Coroners Court of Victoria
65 Kavanagh Street
SOUTHBANK Vic 3006

Hearing Dates: 17 to 19 September 2014

Findings of: JOHN OLLE, CORONER

Representation: Mr Paul Halley of Counsel for Frank Rosato
Mr Sean Cash of Counsel for the Northern Hospital
Mr Simon Martin of Counsel for Health Care Imaging
Services
Ms Fiona Ellis of Counsel for Dr Paul Tauro

Police Coronial Support Unit Leading Senior Constable Cristiano

I, JOHN OLLE, Coroner having investigated the death of ZORAN GEORGIEVSKI

AND having held an inquest in relation to this death on from 17 to 19 September 2014

at Coroners Court MELBOURNE

find that the identity of the deceased was ZORAN GEORGIEVSKI

born on 3 September 1970

and the death occurred on 7 April 2011

at 15 Mendip Street, Reservoir 3073

from:

- 1 (a) HAEMOPERICARDIUM COMPLICATING ASCENDING THORACIC AORTIC DISSECTION

in the following circumstances:

1. Mr Zoran Georgievski was aged 40 years at the time of his death. An Associate Professor, described as an academic leader in orthoptics and a strong advocate of his profession, he is survived by his partner Frank Rosato, parents Spase and Menka and brother Tom, all of whom he maintained close and loving relationships.

Overview

2. On 4 April 2011 Zoran felt chest tightness – like someone was sitting on his chest. He described feeling pain in his throat and tingling in his left hand. The pain resolved spontaneously in five to ten minutes. An ambulance was called and Zoran was transported to the Northern Hospital. En route he was given intravenous morphine 2.5 mg with effect.¹
3. Zoran was admitted to the Emergency Department ('ED') at the Northern Hospital at 23:43 hours.² ('the Admission'). He was examined by Dr Jayatileka.³ Dr Jayatileka's impression was that Zoran was suffering "' Cardiac ischaemia, ? reflux". She noted Zoran's history of anxiety but referred to the need to exclude a cardiac cause for his presentation.⁴ Specific

¹ Northern Hospital medical records p 39

² Northern Hospital medical records p 24

³ see notes of examination recorded in Northern Hospital medical records at pp 31-2

⁴ Northern Hospital medical records p 32

blood tests were ordered to determine if there was an elevation in cardiac enzymes which may indicate that Zoran had experienced a cardiac event.⁵

4. At approximately 00:22 hours on 5 April 2011 the request for a chest x-ray was registered on the computer system in the radiology department at the Northern Hospital.⁶ The chest x-ray was performed at 00:59 hours and the image available on the computer system at 01:20 hours.⁷
5. At 03:15 hours Zoran was admitted to the Short Stay Unit ('SSU') within the Northern Hospital. Blood testing for cardiac enzymes was repeated at 06:00 hours on 5 April 2011. Sometime between 09:00 and 10:00 Zoran was reviewed by consultant emergency physician Dr Mok. There is a note in the medical discharge summary that Zoran's chest x-ray had been reviewed and that no abnormalities had been detected.⁸
6. Zoran was discharged from the Northern Hospital at 10:50 hours on 5 April 2011. His principal diagnoses were of chest / epigastric pain. He was prescribed medication for reflux (Somac) and aspirin. There was a note for Zoran's general practitioner to arrange for an outpatient stress test and gastroscopy.⁹
7. On the following days, Zoran consulted his GP and following referral, a cardiologist. On the morning of 7 April, Zoran woke at 06:30 hours and saw Frank off to work. During the morning attempts to telephone Zoran were unsuccessful. At 10:00 hours, at Frank's request, Zoran's parents attended the house. They gained access to find Zoran lying on the floor of his study, unresponsive and not breathing. Under instruction of the triple zero operator they performed CPR until paramedics arrived and continued CPR. Sadly, Zoran could not be resuscitated.

POST-MORTEM EXAMINATION

8. A post-mortem examination and report was conducted by Dr Matthew Lynch, Senior Forensic Pathologist at the Victorian Institute of Forensic Medicine. Dr Lynch reported that the cause of death is haemopericardium which has occurred as a consequence of rupture of a dissecting aneurysm of the ascending aorta onto the pericardial sac. This has resulted in

⁵ see results for Troponin I and CK recorded in the Northern Hospital medical records at p 6

⁶ see Exhibit 9, Attachment 'A' – "central chest pain at 2230 @ rest"

⁷ see Exhibit 9 (statement of Dr. Tauro) Attachment 'B'; see also Northern Hospital medical records p 11

⁸ Northern Hospital medical records p 26

⁹ Northern Hospital medical records p 27

cardiac tamponade a process whereby the sac surrounding the heart fills with blood thus preventing it from bearing effectively.

9. Upon review of the medical records, Dr Lynch referred a chest x-ray taken at the Northern Hospital following Zoran's complaint of chest pain and subsequent admission, to Dr Chris O'Donnell, Diagnostic Radiologist who described the mediastinum as being widened.
10. Dr Lynch determined that the cause of death is 1(a) haemopericardium complicating ascending thoracic aortic dissection.

Purpose of the Coronial Investigation

11. The primary purpose of the coronial investigation of a reportable death¹⁰ is to ascertain, if possible, the identity of the deceased person, the cause of death (interpreted as the medical cause of death) and the circumstances in which the death occurred.¹¹ An investigation is conducted pursuant to the *Coroners Act 2008 (Vic)*¹² and the outcome of this part of my investigation is included in this finding.
12. Coroners are also empowered to report to the Attorney-General on a death they have investigated; the power to comment on any matter connected with the death, including matters relating to public health and safety or the administration of justice; and the power to make recommendations to any Minister, public statutory or entity on any matter connected with the death, including recommendations relating to public health and safety or the administration of justice.¹³ This is referred to as the 'prevention role' of the coroner.
13. A coroner's role is to seek and establish the facts set them out and for others, if they wish to draw legal conclusions. It is not the role of the coroner to determine who contributed to a death, due to the connotation that has historically attached to that concept; a connotation of fault, blame or culpability. I have assiduously sought to avoid drawing legal conclusions.

¹⁰ Section 4 of the *Coroners Act 2008 (Vic)* requires certain deaths to be reported to the coroner for investigation. Apart from a jurisdictional nexus with the State of Victoria, the definition of a reportable death includes all deaths that appear 'to have been unexpected, unnatural or violent or to have resulted, directly or indirectly, from accident or injury. Mrs Mulqueen's death falls within this definition.

¹¹ *Coroners Act 2008 (Vic)* s 67.

¹² Hereafter referred to as 'the Act'.

¹³ *Coroners Act 2008 (Vic)* sections 72(1), 72(2) and 67(3).

14. The *Briginshaw*¹⁴ standard of proof is applicable to findings of fact in this Court. As Dixon J espoused:

The seriousness of an allegation made, the inherent unlikelihood of an occurrence of a given description, or the gravity of the consequences flowing from a particular finding are considerations which must affect the answer to the question whether the issue has been proved to the reasonable satisfaction of the tribunal. In such matters 'reasonable satisfaction' should not be produced by inexact proof, indefinite testimony or indirect inferences.¹⁵

The Evidence

15. This finding is based on all the investigation material comprising the coronial brief of evidence, all material obtained after the provision of the brief, the statements and evidence of those witnesses who appeared at the inquest and any documents tendered through them, as well as any other documents provided through counsel and submissions of counsel.

16. The following witnesses gave evidence at the inquest:

- Dr Kavindri Jayatileka
- Dr Paramentiran Ramanathan
- Dr Lisa Lim
- Dr Michelle Mok
- Dr Chris O'Donnell
- Dr Paul Tauro
- Dr Shyaman Menon
- Associate Professor Oliver Hennessy

Submissions

17. Written submissions of all members of counsel have greatly assisted my investigation.
18. Not every submission is specifically referred to in my Finding, however all have received my careful consideration.

¹⁴ *Briginshaw v Briginshaw* [1938] 60 CLR 33.

¹⁵ *Briginshaw v Briginshaw* [1938] 60 CLR 33 [362]-[363].

Focus of Inquest

I have focused my investigation on the following:

- Medical management of Zoran during the admission with particular emphasis on the failure to diagnose aortic dissection; and
- Failure (by ED clinicians and by consultant radiologist Dr Paul Tauro) to identify the widening of the upper mediastinum on chest x-ray.

19. At the commencement of the inquest, it was evident that most of the facts about Zoran's death are known including his identity, the medical cause of his death and aspects of the circumstances, including the place and date of his death.

Evidence at Inquest

20. Mr Halley has accurately set out the history signs and symptoms of Zoran's symptoms following admission:

- History of hypertension;
- Severe chest pain of sudden onset;
- Chest pain maximal at onset;
- Central (retrosternal) chest pain;
- Pain radiating to the throat;
- Pain that stopped/resolved spontaneously;
- Pain that changed position (here the pain became epigastric pain);
- Epigastric pain not similar to reflux;
- Diaphoresis (sweaty);
- Clamminess;
- Anxiety; and
- Tingling in his left hand (a neurological symptom) ("the presenting history, signs and symptoms").

21. Dr Jayatileka, a resident on her third day in the ED, performed the initial assessment of Zoran. She acknowledged she did not consider aortic dissection as a differential diagnosis. In consideration of her limited experience, Dr Jayatileka performed a reasonable assessment

of Zoran. She ordered appropriate tests, including chest x-ray. Importantly, she faithfully discussed her assessment with the senior registrar Dr Ramanathan. Of note, Dr Ramanathan did not consider aortic dissection as forming part of the differential diagnosis.

22. Dr Ramanathan viewed the film in evidence. Mr Halley submits:

“Dr Ramanathan gave evidence that the chest x-ray was borderline in terms of mediastinum, in that the mediastinum is “*slightly enlarged*”.¹⁶

On the basis of the chest x-ray finding Dr Ramanathan gave evidence that he would have undertaken a history and examination of Mr Georgievski himself with a view to performing a CT aortogram.¹⁷ Dr Ramanathan did not undertake a history examination Mr Georgievski himself.

Dr Ramanathan gave evidence that it would have been the responsibility of Dr Lim, overnight resident, to check the chest x-ray given that the care of Mr Georgievski had been handed over to her by Dr Jaytileka.¹⁸ However, the evidence is unclear as to whether the fact that a chest x-ray had been ordered on Mr Georgievski was handed over to Dr Lim. Dr Lim’s best guess was that it was not handed over to her.¹⁹ Dr Jaytileka conceded that she had “*no basis at all*” to say that she requested the chest x-rays be reviewed at the handover of Mr Georgievski’s care.”

23. I am unable to determine whether the hand over from Dr Jaytileka to Dr Lim included chest x-ray.

24. At the time of Zoran’s admission, ED clinicians were not informed when radiology results were available on the ED computer. Regrettably no member of the clinical staff in ED sighted Zoran’s film prior to his transfer to SSU.

25. Dr Ramanathan did not consider Zoran’s presentation indicative of aortic dissection. Nonetheless, had he seen the film, he believes he would have performed a history examination and may have ordered a CT aortogram. Whether or not Dr Ramanathan’s history examination would have led him to order a CT aortogram, his failure to view the

¹⁶ T63. 1-9

¹⁷ T63. 10-15

¹⁸ T59. 10-16

¹⁹ T94. 19-21

film was a missed opportunity to consider the implementation of diagnostic measures which may have diagnosed and led to the repair of the aortic dissection.

Short Stay Unit

26. Dr Mok understood that Zoran was admitted to the SSU “after his blood tests and chest x-ray were reviewed by the ED medical officer”.²⁰ Further, her reasonable expectation was Zoran would not have been admitted to the SSU unless his chest x-ray was normal.

27. Mr Halley accurately submits:

“In evidence she could not say that she definitely reviewed the chest x-ray and that given that a patient does not go onto the Short Stay Unit with an abnormal chest x-ray, she may not have reviewed the chest x-ray.”²¹ It was put to Dr Mok that Mr Georgievski’s mother was with him the whole time while he was in the Short Stay Unit and that Dr Mok did not look at any computer screen while at the bedside with him, to which Dr Mok responded “I can’t recall”.²² Further she conceded that if she did review the chest x-ray she would have done so from a mindset of the chest x-ray being reviewed previously and found to be normal.²³

Further she conceded that:

- a) Reviewing the chest x-ray on a portable computer screen would not be as good as reviewing the chest x-ray on a standard size and resolution computer screen, because of the smaller screen size and smaller resolution;²⁴
- b) Reviewing the chest x-ray on a portable computer screen would put her at a disadvantage when reviewing the chest x-ray;²⁵
- c) The chest x-ray should have been reviewed on a standard size and resolution computer screen;²⁶

²⁰ Exhibit 5

²¹ T110; T116

²² T137 -138

²³ T112 -113

²⁴ T113. See also Dr Menon at T284

²⁵ T113

²⁶ T113

- d) Abnormalities on a chest x-ray are more visible on a standard size and resolution computer screen,²⁷
 - e) If she had been made aware that no one had reviewed the chest x-ray on a standard size and resolution computer screen, she would have done so herself.²⁸
28. Zoran should not have been admitted to SSU without his chest x-ray being viewed by ED clinicians. I accept the consensus of the expert witnesses, that residents or registrars, irrespective of their seniority, may not be able to detect the abnormality revealed on Zoran's film. Nonetheless, Dr Mok should have viewed the film and satisfied herself there was no abnormality.
29. At the time of discharge, Dr Mok either viewed the film and failed to detect the abnormality on the low resolution bed-side screen, or did not view the film, in the reasonable but incorrect belief ED clinicians had already cleared the film of abnormality. Irrespective, an opportunity was lost to potentially implement diagnostic measures which may have led to diagnosis and repair of aortic dissection.
30. Dr Mok discharged Zoran from the SSU at 10.50 am on the 5 April 2011.
31. She considered epigastric pain suffered by him as similar to reflux symptoms. At inquest, Dr Mok conceded that a notation of Dr Jayatileka that Zoran's pain was different to reflux was indicative that the epigastric discomfort suffered by him at the time of discharge was in fact the result of progression of his aortic dissection.
32. Systems failures culminated in missed opportunities to diagnose aortic dissection. Notably, I have no comfortable satisfaction that the film of Zoran's chest x-rays were seen by any member of clinical staff, prior to discharge. However, I endorse the following submission of Mr Cash:

The expert evidence suggests that the medical staff at the Northern Hospital would not necessarily have been expected to detect the abnormality on the Chest X-ray.

Prof Hennessy was asked whether he had an opinion '...in relation to the clinicians in the ED being able to identify this type of finding that you found in this chest X-

²⁷ T113

²⁸ T114

ray'.²⁹ In response, he said he would '...not expect a junior doctor, who had very little exposure to imaging and radiology, to be able to make a diagnosis or a suspected diagnosis of a dissection of the ascending aorta. It is possible that an experienced consultant in accident and emergency could make that or be highly suspicious but a junior doctor, I would not expect them to make that diagnosis. That diagnosis – outside radiology, a diagnosis like that would be more easily made by someone like a cardiac surgeon who is used to looking at chest X-rays, or a chest physician whose sole exposure to imaging is looking at chest X-rays. But a junior doctor in casualty, I would not expect them to make that diagnosis.'³⁰

Dr Menon said that he would not have expected a resident to have been capable of identifying the subtle X-ray findings³¹ and that, although a registrar or consultant could *potentially* have been expected to identify the changes,³² it would all depend upon the level of clinical suspicion.³³ As their clinical suspicion was low, Dr Menon said that they may not have necessarily picked up the abnormality.³⁴

The expert radiologist Dr O'Donnell viewed a copy of the request form and the anterior chest radiograph of Zoran in the AP erect projection performed on 5 April 2011 at the Northern Hospital.³⁵ Of significance, Dr O'Donnell's radiographic findings included the observation of a 'marked widening on the right side of the upper mediastinum in continuity with the aortic knuckle'.³⁶

Dr O'Donnell was asked by Counsel Assisting regarding the ability of an emergency doctor to make the observations that he made.³⁷ According to Dr O'Donnell, the '*marked widening*' of the aorta (to which he referred in his report) was a 'very abnormal finding in a person of that age because that's not normally seen in patients

²⁹ T360

³⁰ T360

³¹ T294

³² T294

³³ T295

³⁴ T295

³⁵ Coronial Brief p15

³⁶ Coronial Brief p15

³⁷ T148

of that age in terms of these conditions, hypertension and diabetes'.³⁸ Dr O'Donnell gave evidence that such a finding was '...quite a subtle finding and in my opinion, junior doctors and/or emergency doctors may not recognise this and I would actually suggest that an average emergency physician, which is the level of which we are trying to assess here – the routine emergency physician, I think, would find this quite a difficult finding. I think this is in the realm of more a specialist's finding. A specialist radiologist's finding'.³⁹

Not being expert in the interpretation of such X-rays, the hospital medical staff were reliant upon the expertise of the radiologist. They would have been entitled to believe that any abnormal X-ray result would have been telephoned through. Dr Hennessy said that he would have rung through such a 'significant abnormality'⁴⁰ (although Dr O'Donnell felt that the finding was not of such a magnitude that an urgent phone call through to the emergency department would have been required⁴¹). On the evidence of Dr O'Donnell, had a phone call been made to the emergency department alerting it to the irregularity in the imaging when Dr Tauro reviewed the imaging at about 14:49hrs on 5 April, the hospital would have communicated with Zoran and got him to return to the hospital for a CT scan.⁴² Likewise, Dr Menon said in evidence that '...if we were alerted to the potential...we would have brought the patient back for a definitive test'.⁴³ Had Zoran returned to the hospital during the course of the afternoon of 5 April, this would have been approximately two whole days before he was found deceased.

33. Although Dr Mok should have viewed the chest X-ray prior to discharging Zoran, I endorse the following submission of Mr Cash:

The evidence indicates that neither of the clinicians would necessarily have been expected to have been able to identify the widened mediastinum on the X-ray image. As Dr Menon said in evidence, '...we do rely on our radiologist that, you know, there

³⁸ T147

³⁹ T148

⁴⁰ T357 to 358,378,381

⁴¹ T149

⁴² T160

⁴³ T294

are subtle changes which might be of clinical significance, which may not have been identified...⁴⁴

34. Mr Martin has accurately detailed the chronology in respect to Zoran's chest X-ray:
- a) the request for his chest x-ray was time stamped 11.59 pm on 4 April 2011;
 - b) the request was entered onto the Radiology Information System at 12.22 am on 5 April 2011;
 - c) the x-ray was completed on the Radiology Information System at 12.59 am on 5 April 2011;
 - d) the x-ray was reported by Dr Tauro at 2.49 pm n 5 April 2011;
 - e) the x-ray was verified by Dr Tauro at 9.02 am on 6 April 2011.⁴⁵

Northern Hospital relied on the expertise of Radiologist to safeguard instances where irregularities on X-rays were not detected by clinicians

35. Northern Hospital submits it was reasonable to expect that the reviewing radiologist would communicate with the clinicians in the event of any concern being identified by the reviewing radiologist.⁴⁶ Dr Menon 'would be anticipating the radiologist to give us a call' as soon as the radiologist identified a 'marked widening' of the mediastinum.⁴⁷ In the circumstances, it was not unreasonable for the clinicians to expect that if there were any irregularities detected on the X-ray, they would be notified accordingly. However, they were not.

Expert Review of Zoran's chest X-ray

36. Ms Ellis has accurately set out evidence in respect to the chest x-ray:

"Dr. O'Donnell, radiologist, prepared a report and gave evidence at the Inquest at the request of the Coroners Court. He reviewed Zoran's chest x-ray and summarised the radiographic findings including reference to a "little rotation" and "marked widening of the right side of the upper mediastinum in continuity with the aortic knuckle."⁴⁸

⁴⁴ T306

⁴⁵ Submissions Health Care Imaging Services

⁴⁶ For example, Dr Menon aluded to this at T307

⁴⁷ 279

⁴⁸ Exhibit 6. Inquest brief p15

Dr O'Donnell was of the opinion that the widening on the right side of the upper mediastinum is typical of ascending aortic dilatation" and "is a very abnormal finding in a patient of only 40 years of age and indicates either intrinsic pathology in the aorta i.e aneurismal dilatation or secondary dilatation due to pathology in the aortic valve such as aortic stenosis or incompetence."⁴⁹

Professor Hennessey, radiologist, prepared a report and gave evidence at the Inquest at the request of the Coroners Court. Professor Hennessey on review of Zoran's chest x-ray concluded that the ascending aorta was abnormal and "in the clinical context suspicious for an abnormality of the ascending aorta."⁵⁰

Dr. O'Donnell described the finding of a widened mediastinum as a subtle finding that was not detectable by the average Emergency Department physician. It was a matter that would be noticed by a specialist radiologist.⁵¹

Both Professor Hennessey and Dr. O'Donnell were of the opinion that the finding of the widened mediastinum should have been reported. Professor Hennessey gave evidence that the responsibility then rests with the clinician (Emergency Department) to initiate further discussion with the radiologist and maybe order further imaging of the patient.⁵²

Dr Tauro prepared a statement⁵³ and gave viva voce evidence at the Inquest. He has no independent recollection of reporting Zoran's chest x-ray in April 2011. Accepting that to be the case Dr. Tauro is unable to say whether the widened mediastinum is a matter that:

- (i) he did or did not see at the time of reporting the chest x-ray;
- (ii) having seen he regarded as a non-specific finding;
- (iii) he saw but attributed to the minor rotation of the patient.⁵⁴

⁵⁰ Exhibit 18, Inquest Brief p 44

⁵¹ T148; see also evidence of Professor Hennessey at T360

⁵² T360

⁵³ Exhibit 9

⁵⁴ T213 & 238

37. Ms Ellis and Mr Halley addressed the issues of hindsight bias and perceptual error. Reports and opinions of Professor Pitman and Dr Wriedt were obtained by Ms Ellis' instructing solicitors.

38. Ms Ellis submits:

It can reasonably be inferred that Professor Pitman and Dr Wriedt suspected that something had gone awry with one if not more of the subjects of the blind reads given that the request to engage in the process had come from the solicitors. Accepting the imperfections attending upon the blind reads it is submitted that they offer some assistance to the Court by demonstrating the nuances and difficulties faced by radiologists engaged in the real time reporting of x-rays together with an understanding of the phenomena of both hindsight bias and perceptual error.

39. For his part, Mr Halley submits:

Much was made by Dr Tauro regarding the concept of hindsight bias and the reliability of interpreting radiology retrospectively.

Both Dr O'Donnell and Professor Hennessy are well experienced radiologists who are well aware of the pitfalls of hindsight bias which was taken into account whilst compiling their respective reports.⁵⁵

Mr Halley challenges such evidence as presented on the part of Dr Tauro in relation to a blind view of Mr Georgievski's chest x-ray was replete with biases such as:

- a) Providing paper copies to experts rather than high resolution screens to approximate Dr Tauro's viewing conditions;⁵⁶
- b) Providing a group of x-rays to experts with prominent ascending aortic contour which would not be a common scenario in everyday practice;⁵⁷
- c) Perceptual bias of experts;⁵⁸
- d) Failing to provide the very important piece of information to experts that Mr Georgievski was a 40 year old man (information available to Dr Tauro);⁵⁹

⁵⁵ T206 -207 (per Dr O'Donnell)

⁵⁶ See T205 generally

⁵⁷ T205 -206

⁵⁸ T206 -207

- e) Of the set of x-rays provided to the experts all were photographs apart from Mr Georgievski's which was a photocopy.⁶⁰

Mr Halley concludes, instructively, Professor Hennessy carried out his own blind review of Mr Georgievski's chest x-ray by giving the chest x-ray to four radiologists with a background of man in his 40's with chest pain. Each of the four radiologists reported a widened mediastinum.⁶¹

40. Professor Hennessy did not provide the radiologists with any further information, notably they were not provided with the clinical outcome.
41. Professor Hennessy and O'Donnell accepted that hindsight bias is phenomena that is particular to radiology.⁶²
42. Ms Ellis submits that Professor Pitman, Dr Wriedt and Dr Tauro interpreted Zoran's film differently. Professor Pitman noted the prominence of the ascending aorta which he attributed to rotation, Dr Wriedt and Dr. Tauro do not refer the prominence of the ascending aorta or rotation. Professor Hennessey, Dr. O'Donnell and the four radiologists who performed the blind review with the request of Professor Hennessey all identified the widened mediastinum. Ms Ellis noted Professor Hennessy, when asked about the varied reports stated:

"That's a fact of life and that's what radiology reporting is. The degree of rotation and the prominence of both the ascending and descending thoracic aorta on chest x-rays is very high...particularly in old people...it's not an uncommon finding."⁶³

43. If Dr Tauro had interpreted the chest x-ray correctly I am satisfied he would have immediately telephoned the ED to enable Zoran to be recalled. This would have been the expectation of both Professor Hennessy and Dr Menon.
44. I endorse the following submission of Mr Halley in respect to CT aortogram:

⁵⁹ T207

⁶⁰ T245-246

⁶¹ T361-364

⁶² 64T 168

⁶³ T380

- a) On 4 April 2011 (on the basis that if the chest x-ray have been viewed by Dr Ramanathan he would have undertaken a history and examination of Mr Georgievski with view to performing a CT aortogram);
- b) On the morning of 5 April 2011 (on the basis that Mr Georgievski should not have been discharged when still in pain, having not been examined by the consultant Dr Mok and having not had his chest x-ray viewed at all, or in the alternative not having his chest x-ray viewed on a full size and full resolution computer screen, which would have revealed a widened ascending aorta/mediastinum);
- c) On the afternoon of 5 April 2011 (on the basis that Dr Tauro should have identified and reported on the abnormal widening ascending aorta and immediately informed the emergency department by telephone leading to Mr Georgievski being recalled to the emergency department);
- d) In the alternative to (c), on 6 April 2011 (on the basis that Dr Tauro should have identified and reported on the abnormal widening ascending aorta and with a turn over of informing the emergency department within 24 hours);

Had a CT aortogram been performed on 4 April 2011 or 5 April 2011 (or indeed 6 April 2011), it would have revealed an aortic dissection.⁶⁴ This would have led to a referral to a cardiothoracic surgeon.⁶⁵

45. Mr Cash submitted that clinicians appropriately ordered a chest x-ray and were entitled to rely upon the advise of the consultant radiologist:

“Upon accurate interpretation, the Chest X-ray revealed a widened mediastinum. The existence of the widened mediastinum mandated further investigation which would have been likely to confirm a dissecting aorta. Unfortunately, the Northern Hospital was not notified - and ultimately misinformed - by the responsible radiologist as to any abnormality in the CXR. Had the hospital been alerted to the abnormality, further investigation would no doubt have been undertaken and the aortic dissection likely identified.”

46. Mr Cash submits:

⁶⁴ T77 (per Dr Ramanathan)

⁶⁵ T77 (per Dr Ramanathan)

“The medical management provided to Zoran by the Northern Hospital should be viewed in its proper context. Zoran’s clinical presentation was an atypical example of an extremely rare presentation / condition. As such, upon a proper risk stratification, any clinical suspicion of an aortic dissection would have understandably been low based on the clinical presentation alone. In terms of the radiology, the clinicians could not have been expected to have had the degree of expertise required to identify or interpret the actual abnormality which was ultimately identified on the chest x-ray which would have suggested the need for further investigation. Even if the hospital medical staff had viewed the imaging of the chest x-ray after it became available on the computer during the early hours of 5 April, their justifiably low level of clinical suspicion was such that they understandably may not have identified any abnormality. In this regard, the clinicians were understandably reliant upon the expert and timely advice of the responsible radiologist.

Zoran’s clinical presentation was atypical of someone who was experiencing an aortic dissection.”

Aortic Dissection must be considered as a differential diagnosis for chest pain

47. Mr Cash referred to the evidence of Dr Shyaman Menon:

“Dr Menon said that whilst aortic dissection should be in any differential diagnosis of someone with chest pain, the clinician needs to make a risk stratification.⁶⁶ The tenor of his evidence was that it was understandable that the clinical suspicion would have justifiably been low given the circumstances. Not surprisingly therefore, Dr Ramanathan’s evidence was that ‘...going through the notes and the description of the pain, prospectively, I wouldn’t have thought it’s a dissection’.⁶⁷ Likewise, Dr Mok said that the description and course of events suggested to her that it was very unlikely to be a dissecting aorta and more in keeping with the classic signs of a cardiac event.⁶⁸

Reference was made by Ms Ellis during the proceedings to the article of Dr Eddey where Dr Eddey states that ‘The radiographic findings classically associated with

⁶⁶ T292

⁶⁷ T64

⁶⁸ T108

thoracic aortic dissection are not reliably present and their absence is not sufficiently sensitive to rule out aortic dissection'.⁶⁹ Dr O'Donnell agreed with this⁷⁰ and accepted that a proportion of patients with aortic dissection may still have a normal chest X-ray result.⁷¹ In this regard, Dr O'Donnell agreed that the clinicians are in the best position to make a judgment about whether something further needs to be done as the clinicians are able to make a clinical assessment of the patient.⁷² It is submitted that whilst this is undoubtedly true, the clinical picture was not necessarily suggestive of aortic dissection. Furthermore, to the extent that Dr O'Donnell was invited to accept that, ultimately, '...it's really a matter of noting the prominence of the ascending aorta?',⁷³ the clinicians received no assistance from Dr Tauro in this regard. Had they done so, the outcome may well have been very different.

Errors in diagnostic imaging

48. Professor Hennessy explained that the phenomena of perceptual bias is not peculiar to radiology, however it is a known issue that relates to reporting. He explained radiologists look at lines, shadows, and images and stressed there is no other specialty in medicine that has that difficult task. In his view most of the areas related to perception rather than interpretation.

49. Professor Hennessy noted that the error rate in radiology has not improved since the 1940's and today it remains a staggering 30 - 40% in images which have an abnormality. He explained:

"... it is not understood why we, as radiologists, and I include myself in that, make errors everyday of the week, when we do. It is to do with perception and that's physiological, psychological and environmental."⁷⁴

50. Professor Hennessy rejected Dr Tauro's possible explanation for missing the widening of the mediastinum due to the projection being anterior / posterior.

⁶⁹ T200

⁷⁰ T200

⁷¹ T202

⁷² T201

⁷³ T201

⁷⁴ T370

51. Though observing Dr Tauro's power point in respect to rotation, and accepting the proposition the more relevant clinical information provided to a radiologist the better, and acknowledging that:

“the percentage of prominent aorta, both the ascending, the arch of the aorta, and the descending, is high in particular in old people.... is not uncommon finding,”

Professor Hennessy distinguished Zoran's film from the main stream:

“if the patient is of an age group and has an abnormal finding and I think is related to a vessel, that I would stress in my report, as I did this here, and I would act further.”⁷⁵

52. Noting it is rare that a radiologist receives a clinical request query aortic dissection, Professor Hennessy explained upon sighting Zoran's film:

“The first thing I would say is I don't have an awful lot of clinical information of chest pain, but I'm worried... then I would say that, that chest x-ray, my interpretation is I am worried about the ascending aorta. Have you considered that this patient might have aortic dissection or what else?” ... I wouldn't spend a lot of time discussing it. I would give him my expert advice. I am not saying I am an expert but I would give my advice saying, “ You need to request a CT aortogram.”⁷⁶

53. Professor Hennessy remained steadfast. Zoran's chest X-ray abnormality required an immediate telephone call to the referring clinician.⁷⁷

Finding

54. Zoran's chest x-ray was abnormal, revealing a widened mediastinum. If the abnormality on chest x-ray had been detected, diagnostic measures could have been implemented to diagnose and repair Zoran's aortic dissection.

55. I am unable to ascertain why Dr Tauro missed the widened ascending aorta. Possibilities include but are not limited to perceptual error, over emphasis on minor rotation or simple misjudgement. In evidence Dr Tauro highlighted the potential impediment to identification of abnormalities, posed by rotation. In general terms, I take no issue with Dr Tauro's evidence in this respect. However, in respect to Zoran's chest x-ray, I do not consider

⁷⁵ T380

⁷⁶ T381-382

⁷⁷ T 383

rotation a likely explanation for the failure of a consultant radiologist of Dr Tauro's seniority to interpret the marked abnormality on Zoran's chest x-ray. I consider the more likely explanation is perceptual error.

56. The phenomenon of perceptual error in radiology is real. The incidence rate in which it occurs in respect to abnormal findings is high (30-40%).
57. I am satisfied that Dr Tauro, an eminent senior radiologist, reviewed Zoran's chest x-ray but missed a marked significant abnormality. Had he noted the widening of the right side of the upper mediastinum on Zoran's chest x-ray, he would have immediately contacted clinical staff, leading to Zoran's return to hospital and the conduct of a CT aortogram and likely diagnosis and repair of his aortic dissection.

Initiatives undertaken by Northern Hospital

58. Graphically illustrating the determination of the Northern Hospital to learn and improve, Dr Menon detailed a range of significant initiatives which have been implemented at the Northern Hospital, subsequent to Zoran's death.

Handover

59. Since 2011, significant changes have been put in place in relation to handover processes.⁷⁸ At the time of Zoran's admission, there were three medical handovers led by a senior clinician that occurred throughout the day in a meeting room away from the clinical floor but within the department. That has now progressively changed to four formalised handovers throughout the day conducted at the patient's bedside and led by a consultant. The patient now has greater input into the medical handover.

Pilot program to consolidate documentation

60. Dr Menon referred to a pilot program that is currently being developed by the Northern Hospital which is designed to address a desire to consolidate documentation into one platform, thereby minimising duplication.⁷⁹

Resident now on site in the SSU

61. At the time of Zoran's admission, there was a resident in the SSU between 7.30am until 1.00am⁸⁰ and if a patient was admitted to the SSU after 1.00am, the patient remained under

⁷⁸ T323

⁷⁹ T326

the treating doctor and the treating doctor would handover that patient to the SSU resident at 7.30am the following morning.⁸¹ There was no formal handover to the SSU at the time of Zoran's admission.⁸² Nowadays there is a resident on site in the SSU between 7.30am and 11.00pm.⁸³

Now a formalised handover to the SSU resident

62. At 10.30pm there is a formalised handover to a dedicated SSU resident who is thereafter the point of contact in the SSU⁸⁴. The dedicated SSU resident carries a pager so that the SSU team can be contacted.⁸⁵ A further formalised handover occurs at 7.30am back to the new SSU day resident.⁸⁶

SSU resident is paged by nursing staff immediately concerns are raised

63. The resident assigned to the SSU is contactable by pager if any SSU nursing staff have any concerns.⁸⁷ Furthermore, if a patient meets the clinical instability criteria, there is an escalation process that has been instituted whereby nursing staff in the SSU would call the registrar to come and assess the patient within 15 minutes.⁸⁸

A dedicated emergency physician is now required to independently assess the patient

64. In relation to the SSU, nowadays between 7:30 am and 11:00 pm, a dedicated emergency physician is required to independently assess the patient.⁸⁹ Between 11:00 pm and 7:30 am, a registrar takes on the same mantle.⁹⁰

Prior to SSU admission, X-rays will be reviewed by a senior doctor

65. Dr Menon noted that nowadays, before a patient is admitted to the short stay unit, there is an expectation that any X-ray that has been ordered will be reviewed by a senior doctor.⁹¹

⁸⁰ T326

⁸¹ T326

⁸² T326

⁸³ T327

⁸⁴ T327

⁸⁵ T327

⁸⁶ T327

⁸⁷ T288

⁸⁸ T288

⁸⁹ T287

⁹⁰ T287

The implementation of Clinical instability criteria in the SSU

66. If a patient falls into a physiological observation, considered beyond normal parameters, clinical instability criteria have been implemented in the SSU, a response is triggered to the registrar.⁹² Importantly, the observation charts have been changed in order to more readily recognise the instability criteria.⁹³

Northern Hospital are undertaking pilot program, notably to ensure X-ray results are clinically reviewed on receipt

67. Dr Menon referred to a number of pilot programs currently being undertaken by the Northern Hospital, which relate to the emergency clinical record, in addition to built-in notification.⁹⁴ Records are being standardised into the one platform in order to eliminate risks⁹⁵ and that “smarts” have been piloted which relate to the notification of results.⁹⁶ Dr Menon explained that if a patient has, for example, pathology results (eg. blood tests) and the results are back to be viewed, a notification comes up to say that the results are available and to be actioned.⁹⁷ It is envisaged that, in relation to radiology, as soon as an X-ray is done, a signal will be conveyed to alert the clinician to the fact that the radiology is ready to be viewed on the computer screen.⁹⁸ If the clinician doesn't ‘accept or reject’ the notification, there is an ‘escalation process’ such that the consultant (or nursing staff after hours) shall receive a notification within a short period of time (say, 20 minutes).⁹⁹

The radiology request form has been improved

68. The radiology request form has been changed.¹⁰⁰ A clinical question has been added to it. In Zoran's case, the clinician might ask ‘Exclude Aortic Dissection?’.¹⁰¹

⁹¹ T282

⁹² T3298

⁹³ T329 – See Exhibit 16 ‘Emergency Department SSU Adult ObservationChart.’

⁹⁴ T330 In the course of doing so, Dr Menon referred to Exhibit 17 ‘ED Clinical Record with Notifications’.

⁹⁵ T330

⁹⁶ T331

⁹⁷ T331

⁹⁸ T332

⁹⁹ T332

¹⁰⁰ T336

¹⁰¹ T337

69. Dr Menon referred to how in future it is proposed that pathology and radiology ordering is to be conducted electronically so that, inter alia, the request is legible.¹⁰²

Clinicians no longer have to wait for the typed radiologist report

70. Clinicians now have access to a verbal radiology report following the dictation of the report (and before it is typed).¹⁰³

Clinicians are now trained to think Aortic Dissection

71. Dr Menon said that the Northern Hospital has changed the way that it educates its junior doctors by training them to be aware of the potential red flags that should alert them to start thinking about the possibility of aortic dissection.¹⁰⁴

X-ray images are reviewed daily to ensure abnormality's are not missed

72. Dr Menon adverted¹⁰⁵ to how clinicians conduct a review of images at 13:00 hrs daily in conjunction with the clinical notes with a view to determining whether any abnormality has been identified. If not, the matter is followed up. If the patient has been discharged, the patient is called back to the hospital.

73. Further to the above, a more detailed report on the changes implemented from the Clinical Program Director of the Emergency Department at the Northern Hospital, Associate Professor William van Gaal, is annexed to these submissions, and attached to my Finding.

74. The various experts highlighted the difficulty faced by clinicians to diagnose aortic dissection. According to Dr O'Donnell, clinicians '...need all the help they can get. It's a difficult diagnosis and a rare diagnosis.'¹⁰⁶ I endorse Counsel for Northern Hospital submission that unfortunately, the clinicians' attempts at diagnosing Zoran's condition weren't helped by the fact that it was extremely rare, clinically atypical and the widened mediastinum was not identified by the reporting radiologist.

75. Dr Tauro's report found no abnormality detected. Clearly, the marked abnormality should have been included in Dr Tauro's report, together with a comment to consider a CT scan.

¹⁰² T333

¹⁰³ T337

¹⁰⁴ T291

¹⁰⁵ T306

¹⁰⁶ T200

Conclusion

76. Zoran's death was preventable. Zoran's best chance of survival was timely diagnosis and appropriate intervention. For the reasons identified in this finding, diagnostic tools which were readily available to diagnose and treat aortic dissection were not implemented.
77. For Zoran's partner, parents and brother his death is a tragic loss. The response of Northern Hospital reflects a determination to learn lessons and through this coronial process, hope to disseminate those lessons; in particular the need to educate clinical staff to assist the diagnosis of aortic dissection.
78. I note that in the finding into the death of Constandia Petzierides (COR 2010 1571) recommendations were made by Coroner Spanos regarding best practice in ED's with regard to improving the diagnosis and survival of patients with aortic dissection. Her Honour had noted that aortic dissection is a rare disease with significant mortality, even when diagnosed and treated in a timely manner. She stressed the need for correct diagnosis and commencement of treatment prior to catastrophic rupture. I wholeheartedly endorse Her Honour's recommendations.
79. Of the commendable initiatives undertaken by the Northern Hospital subsequent to the tragic death of Zoran I consider most important the emphasis on educating clinical staff as to consider aortic dissection as a differential diagnosis for chest pain and how to exclude it, together with highlighting the need for clinical staff to be more conscious "of the fact that aortic dissection cannot be excluded simply by reference to the "classical presentation" and should be treated as the subarachnoid haemorrhage of the heart, as suggested by Dr David Eddey in his report in the Petzierides inquest."
80. Finally, I consider it essential that ED clinicians be informed of the staggeringly high error rate in radiology of films which have abnormal results.

RECOMMENDATIONS

Pursuant to section 72(2) of the **Coroners Act 2008**, I make the following recommendation connected with the death:

1. I recommend the Department of Health disseminate to all Victorian Health Services a letter of Northern Health dated November 18, 2014 to the Coroners Court of Victoria entitled Report to Coroner – Northern Health changes to procedures and systems, setting out the initiatives and improvements which have been implemented in the Emergency Department

of Northern Health since the death of Dr Zoran Georgievski on the 7 April 2011.
Attachment 1 to this Finding

I direct that a copy of this finding be provided to the following:


Mr Frank Rosato

To the Family of Zoran Georgievski

Interested Parties


Investigating Member of Victoria Police

Signature:



JOHN OILLE
CORONER

Date: 10 April 2015



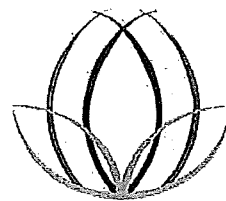
In the Coroners Court of Victoria at Melbourne

Court Reference: COR 2011 1267

Inquest into the death of **Zoran GEORGIEVSKI**

Attachment 1

Our ref: 0521764
Your ref: 1267/2011



Northern Health

18 November 2014

The Registrar
Coroners Court of Victoria
65 Kavanagh Street
SOUTH BANK VIC 3006

BY EMAIL

INQUEST INTO THE DEATH OF DR ZORAN GEORGIEVSKI

Report to Coroner - Northern Health changes to procedures and systems

As requested by the Coroner on 19 September 2014, the following letter sets out the initiatives and improvements which have been implemented in the Emergency Department of Northern Health since the death of Dr Zoran Georgievski on 7 April 2011.

Introduction of new/improved procedures

Implementation of the pilot Patient First Application

Organisational practice and approaches in place at the time of Dr Georgievski's admission

1. At the time of Dr Georgievski's admission, clinicians accessed several information systems in the management of patients in the Emergency Department (**ED**) and Short Stay Unit (**SSU**). The lack of integration meant that staff had to be familiar with a number of programmes and passwords in order to access all of the relevant details regarding a patient's condition and treatment.
2. Clinicians would also be required to document treatment in several platforms, which might involve recording something in the progress notes and then duplicating that information in the discharge letter.
3. Further, a clinician in the management of an ED/SSU patient would need to actively seek out results for investigations conducted based on handover information. There was no notification process for results at the time.

The Northern Hospital **The Northern Hospital**
Parch Health Service 185 Cooper St
Craigieburn Health Service Epping VICTORIA 3076
Broadmeadows Health Service **Phone:** 8405 8000
Bundoora Extended Care Centre **Fax:** 8405 8524

- (b) notification that a doctor is yet to be assigned to a patient or an admission/discharge decision is required (automatic prompt occurs at 2.5 hours post allocation to assigned doctor);
 - (c) alerts which ensure that clinicians are completing patient notes prior to the end of the shift; and
 - (d) an automated clinical instability notification which alerts the treating clinician when the patient's physiological observations fall outside the set parameters.
11. The application will allow tracking of tasks through the course of a patient's treatment in the ED and SSU so that at all times there is an up to date and easily accessible record as to the status of the patient's investigations, including a list of outstanding tasks and which clinician is responsible for actioning them.
 12. The Patient First application is not in use by other emergency departments across the State and is being developed specifically by the Northern Hospital. While the application is currently in its pilot stage, we are hoping that we will shortly have enough information to move the application into production more widely.

Improvements to the handover procedures

Organisational practice and approaches in place at the time of Dr Georgievski's admission

13. At the time of Dr Georgievski's admission, ED patients were handed over from the treating clinician to the incoming clinician in a meeting room away from the clinical area where the patients' beds are located.
14. There was a resident medical officer who was allocated to the SSU during the day shift (0800-1600) and evening shift (1600-0100) and handover of the patients occurred between these shifts. There was no handover of SSU patients overnight and the incoming day resident medical officer was rotated each day allowing for gaps in knowledge of patients, investigations and follow up.

Organisational practice and approaches in place now and planned for future

15. Northern Health recently achieved National Standards Accreditation including Standard 6 - Clinical Handover.
16. Improvements have been made and ongoing evaluation of clinical handover continues in line with accreditation requirements. The ED now has formal bedside handover so that the patient can be involved in the handover and any updated observations discussed at that time. These handovers occur between consultants at 0800, 1600 and 2230 hours.

23. The consistent charts have been implemented. The trial of new refined two-tiered response charts is due to commence in late 2014 or early 2015. The track and trigger charts create an extra system for readily identifying critical changes in a patient's condition and providing the Emergency clinician with further clinical indicators.
24. The next step will be to incorporate the track and trigger charts into the Patient First application in order to generate automatic alerts to the treating clinician when results outside the allowable parameters are recorded.
25. As mentioned above, the nursing team are also able to initiate a review by the treating clinician if they have any concerns about the patient's stability, regardless of whether observations are within the allowable parameters.

Changes to the x-ray referral request form

Practice in place at the time of Dr Georgievski's admission

26. Previously, Radiology forms had a Clinical Comment section to the request form and information recorded in the section was variable.

Practice in place now and planned for future

27. The Radiology request form has been revised to include a Clinical Question. The Clinical Question allows additional information to be provided to the Radiologist reviewing the investigation and can be used to focus the Radiologist's attention on a specific area of concern.
28. A "traffic light" system of request approval has also been implemented to ensure that there is senior clinician input to investigations such as CT or MRI.
29. An additional improvement being developed currently is the extension of the traffic light system to ensure that the results are received and reviewed by the clinician with the appropriate level of seniority and experience.
30. The Radiology request form can now be completed electronically via the Patient First application, minimising any legibility issues arising out of the previous handwritten request forms.


Organisational practice and approaches in place now and planned for future

38. Since mid-2011, the Northern Hospital has run a twice weekly education session for resident medical officers focusing on managing key presenting complaints to the Northern Hospital such as abdominal pain, chest pain, back pain, headache, obstetric emergencies etc. This is a change in the educational style from a traditional teaching concept of illness-based to one based on presenting complaints, in order to highlight the potential red flags in patients who present to the ED and equip our clinicians with the knowledge and skills to risk stratify patients and develop appropriate differential diagnoses.
39. The sessions consist of a dedicated time every Tuesday and Friday for residents and a protected teaching time of every Wednesday for registrars. There are approximately 10-12 topics which are repeated every term in order to allow for the high rate of resident rotation and turnover in the ED.
40. With respect to aortic dissection, we aim to provide more guidance in our sessions as to the appropriateness of aortic dissection as a differential diagnosis for chest pain and how to exclude it. In particular, we are aiming to make our clinicians more conscious of the fact that aortic dissection cannot be excluded simply by reference to the 'classical presentation', and should be treated as the subarachnoid haemorrhage of the heart, as suggested by Dr David Eddey in his report in the Petzierides Inquest. The number of CT imaging requests has increased significantly in recent years as a result of the increasing awareness of aortic dissection and the difficulties involved in diagnosing it.

The Northern Hospital is always striving towards improving the quality of its health services, including by making its treatment more inclusive of the patient, increasing/improving training, automating task management and providing treating physicians with all the tools necessary to provide accurate diagnoses and appropriate management of patients.

We trust that the above information is of some assistance. Please do not hesitate to contact me if you would like any further information concerning the initiatives discussed above.

Yours sincerely,



18/11/2014.

Associate Professor William van Gaal
Clinical Program Director, Emergency Medicine

APPENDIX B

RADIOLOGYRESULT

MESSAGE:

Radiology Results are Ready for a Patient

TASK TYPE:

RadiologyResult

USER TYPE:

Flow Coordinator

TIME REMAINING

ACCEPT ✓ REJECT ✕

Treatment Results: [REDACTED]

Patient

UH Number: [REDACTED]
 Name: [REDACTED]
 DOB: [REDACTED]
 Address: [REDACTED]
 Location: [REDACTED]

Result Details

Service: Abdomen Collected: WA
 Test #: 0740419E1 Received: 201408311056
 Ordered By: Dr SAM HUME (237320AA)
 Test Status: Final results

PLAIN ABDOMINAL X-RAY

Clinical Notes
?Fecal loading.

Report:
 Fecal material was noted in the ascending and descending colon and the rectum.
 Bowel gas pattern was otherwise non diagnostic. No free intraperitoneal gas seen.
 No significant skeletal or soft tissue changes are identified.